

# RESPIRATORY FAILURE ASSOCIATED WITH DISTAL RENAL TUBULAR ACIDOSIS IN AN OLDER ADULT WITH SOUTHEAST ASIAN OVALOCYTOSIS AND CONCOMITANT THYROTOXIC ATRIAL FIBRILLATION

Sii HL<sup>1</sup>, Ng SH<sup>1</sup>, Chiang KH<sup>1</sup> and Wong VF<sup>1</sup>.

<sup>1</sup>Department of Medicine, Hospital Sibul, KM 5 1/2, Jalan Ulu Oya, 96000 Sibul, Sarawak

## Correspondence:

Sii Hoe Leong,  
Department of Medicine,  
Hospital Sibul,  
KM 5 ½,  
Jalan Ulu Oya,  
96000 Sibul, Sarawak  
Email: shl-1031@hotmail.com

## Abstract

Distal renal tubular acidosis (dRTA) is characterized by hyperchloremic hypokalemic metabolic acidosis, nephrocalcinosis and metabolic bone disease. It has been associated with Southeast Asian Ovalocytosis (SAO), particularly in malaria endemic region. We present a case of an older adult with dRTA who presented with respiratory failure as a result of hyperchloremic normal anion gap metabolic acidosis, in association with nephrocalcinosis and SAO. Patient was also diagnosed with new onset atrial fibrillation and thyrotoxicosis. Oxygen therapy was able to be weaned off after treatment with alkali supplementation. Distal RTA may be associated with SAO, and early recognition and treatment of dRTA is paramount in preventing complications such as chronic kidney disease, metabolic bone disease and life-threatening respiratory arrest.

**Keywords:** Distal Renal Tubular Acidosis, Southeast Asian Ovalocytosis, Respiratory Failure, Nephrocalcinosis

## Introduction

Distal renal tubular acidosis (dRTA) is characterized by impaired hydrogen ion secretion from distal nephron, leading to an inability to acidify urine in the presence of hyperchloremic hypokalaemic metabolic acidosis, nephrocalcinosis and metabolic bone disease (1). Mutations in genes encoding transporters involved in transepithelial acid secretion and bicarbonate reabsorption in alpha-intercalated cells have been identified as cause of dRTA (2).

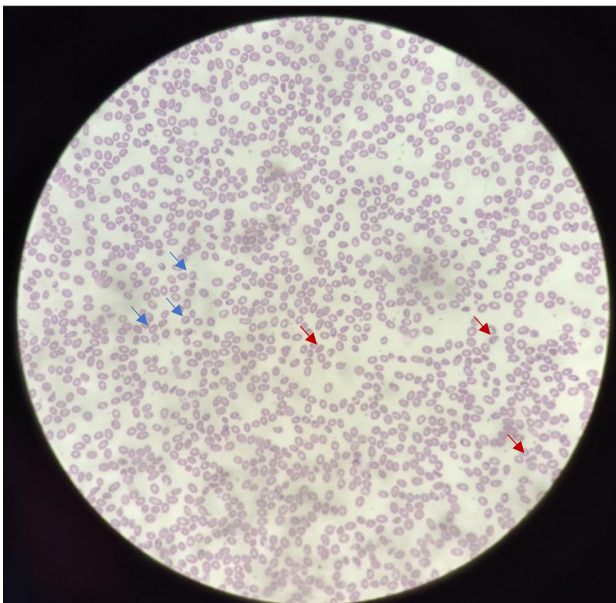
Previous studies have shown that Southeast Asian Ovalocytosis (SAO) is highly prevalent, affecting up to 82% of patients with dRTA (3). SAO is an autosomal dominant erythrocyte abnormality, commonly found in malaria endemic countries, especially southern Thailand, Indonesia, Philippines, Papua New Guinea and Malaysia (4). The condition results from nine band 3 amino-acid deletion due to 27-base deletion of the anion exchanger 1 (AE1) gene in chromosome 17 (5, 6). Band 3 protein or AE1 is a bicarbonate/chloride exchanger expressed in both erythrocytes membranes and basolateral membrane of collecting tubule alpha-intercalated cells, thus, indicating a strong association between SAO and dRTA.

Respiratory failure as a result of muscular weakness due to severe hypokalemia and/or metabolic acidosis was reported as a rare complication in RTA (7). Acute precipitating factors included infection, gastrointestinal losses, glue sniffing, and alcohol intake (7). We report a patient who presented with respiratory failure as a result of severe metabolic acidosis from dRTA despite being treated adequately for respiratory tract infection, new onset atrial fibrillation and thyrotoxicosis. She was diagnosed with dRTA and SAO but without hypokalemia due to concurrent pre-renal acute kidney injury. This case report emphasizes the importance of investigating persistent respiratory failure in patient with SAO and dRTA to prevent life-threatening respiratory arrest from severe metabolic acidosis.

## Case Presentation

A 66-year-old indigenous female from Kanowit, Sarawak, eastern region of Malaysia, with no known medical illness, presented initially with fever, shortness of breath and productive cough with whitish sputum for 4 days. On examination, patient was noted to be tachypneic and clinically dry with poor perfusion. Arterial blood gas analysis showed partially compensated metabolic

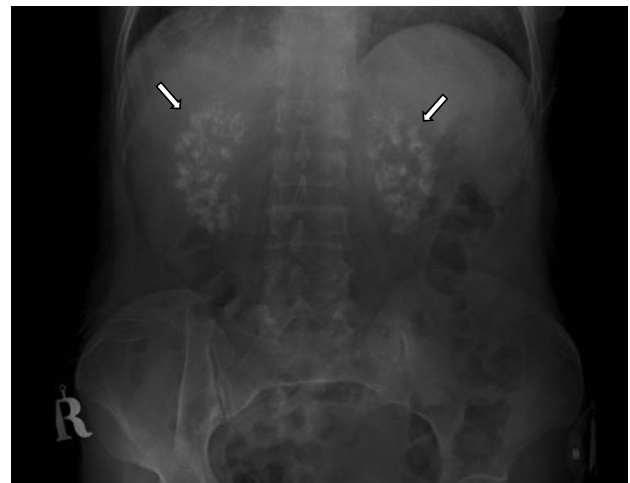acidosis (pH 7.251,  $pO_2$  95.8,  $pCO_2$  23.8,  $HCO_3$  10.2). Serum chloride and potassium were 114 mEq/L and 6.2 mEq/L respectively; with serum urea and creatinine elevated at 14.2 mmol/L and 157  $\mu$ mol/L respectively. Complete blood count showed bi-cytopenia with haemoglobin level of 9.6 g/L and platelet level of  $98 \times 10^9/L$ . Subsequent peripheral blood film showed features of stomatocytes and macroovalocytes which were suggestive of SAO (Figure 1). Electrocardiography noted new onset atrial fibrillation (AF). Left lung lower lobe consolidation which was suggestive of lower respiratory tract infection was demonstrated on chest radiograph. Culture and sensitivity of the blood and sputum as well as oropharyngeal swab for COVID-19 polymerase chain reaction (PCR) were negative. Patient was subsequently initiated on non-vitamin K antagonist oral anticoagulant (NOAC) for AF in view of moderate-high risk of stroke (CHA2DS2-VASc scored 2 for age and gender respectively) and anti-thyroid agents for thyrotoxicosis. She was treated with one course of antibiotic for infection and oxygen supplement was subsequently able to be weaned off. Patient improved clinically with no fever documented throughout admission. Serum urea and creatinine improved to 9.2 mmol/L and 120  $\mu$ mol/L, respectively; serum potassium level normalized to 4.2 mEq/L with adequate hydration.



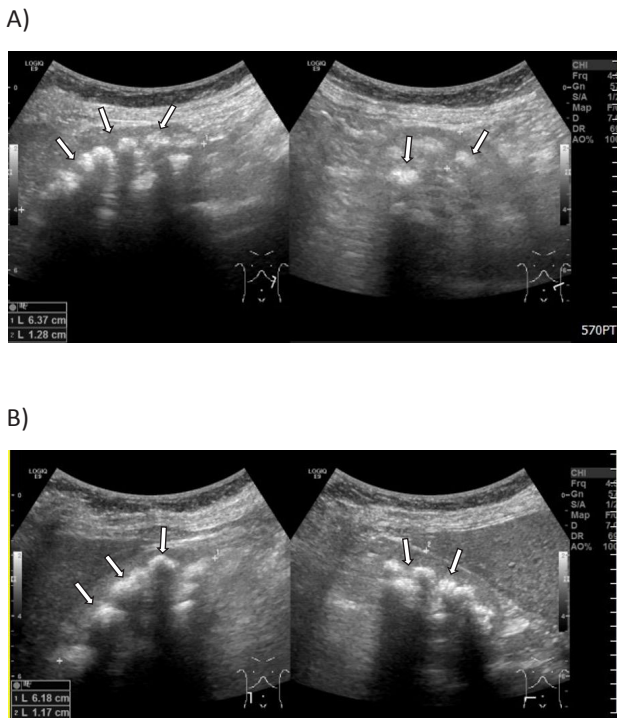
**Figure 1:** Blood film with stomatocytes (blue arrows) and macroovalocytes (red arrows) which are suggestive of Southeast Asian Ovalocytosis (SAO).

On day 7 of admission, patient complained of shortness of breath and desaturated under room air. At that time, patient did not complain of fever, pleuritic chest pain, leg pain or swelling, and failure symptoms such as orthopnea and paroxysmal nocturnal dyspnea. On examination,

patient was tachypneic with respiratory rate of 28 breaths/min under room air, clinically not edematous, not tachycardic; cardiovascular and lungs examination were unremarkable. There was also no evidence of deep vein thrombosis. Repeated arterial blood gas showed type 1 respiratory failure and hyperchloremic metabolic acidosis with respiratory compensation (pH 7.233,  $pO_2$  69,  $pCO_2$  21.5,  $HCO_3$  9.9) and non-invasive ventilation (NIV) was started. Serum chloride and potassium were 117 mEq/L and 4.4 mEq/L respectively. Normal anion gap metabolic acidosis (NAGMA) of 11.5 mEq/L was noted (serum sodium of 134 mmol/L). Urinalysis demonstrated a urine pH of 7.0. Retrospective analysis of the initial arterial blood gas (ABG) on admission also showed hyperchloremic metabolic acidosis. D-dimer sent was negative. Electrocardiography revealed rate-controlled AF and chest radiography did not demonstrate new lung consolidation or features suggestive of acute pulmonary oedema. Evidence of bilateral medullary nephrocalcinosis was demonstrated on X-ray of kidney, ureter, and bladder (Figure 2) and renal ultrasound (Figure 3). A unifying diagnosis of dRTA was made. She was started on Shohl's oral solution and intravenous drip containing sodium bicarbonate. Subsequent blood gas analysis showed resolved metabolic acidosis (pH 7.376,  $pO_2$  119.2,  $pCO_2$  41.5,  $HCO_3$  23.7) and oxygen therapy was able to be weaned off. Repeated culture and sensitivity of the blood and sputum to look for source of hospital acquired infection were negative for bacterial infection. There was no neurological deficit, no family history of renal or renal stone disease. Patient was discharged home after 2 weeks of hospitalization and given follow-up in 3 months at our outpatient medical clinic to review her symptoms with complete blood count, thyroid function test, renal profile, and blood gas analysis.



**Figure 2:** X-ray kidney, ureter, bladder (KUB) shows bilateral nephrocalcinosis (arrows).



**Figure 3:** Ultrasound of left (A) and right (B) kidneys show nephrocalcinosis (arrows).

### Discussion

Distal RTA is characterized by inability of the distal tubule to acidify urine, leading to metabolic acidosis. It is closely associated with complications such as metabolic bone disease, nephrocalcinosis and/or urolithiasis, hypokalemia and chronic kidney disease in older age groups. If it occurs in the pediatric age group, it can lead to growth failure. There is limited evidence to guide diagnosis and management due to its rarity. In our patient, the diagnosis of type 1 dRTA was established with the constellation of alkaline urine (pH > 5.5), normal anion gap hyperchloremic metabolic acidosis, bilateral medullary nephrocalcinosis and its association with SAO. Absence of hypokalaemia on initial presentation was attributed to pre-renal acute kidney injury with raised urea and creatinine level complicated from lower respiratory tract infection.

According to the recent data from Ministry of Health, Malaysia, the highest number of malaria cases were reported from East Malaysia with the highest incidence rate seen in Sarawak (0.420/1000), followed by Sabah (0.383/1000) over a 5-year duration (8). More than one-third of the malaria cases were reported among indigenous population in Sarawak (8). Hereditary conditions affecting the morphology of red blood cells such as thalassaemia, glucose-6-phosphate dehydrogenase deficiency and SAO are believed to render natural protection in indigenous population in areas with high incidence of malaria. SAO has been reported with a prevalence of 4% within the Malays in Kelantan, northeast region of peninsular Malaysia (3), while other parts of Southeast Asia such as Indonesian island of Sulawesi and Thailand reported higher prevalence rates, ranging from 12% to 30% (4, 9).

SAO and dRTA have been demonstrated to share common genetic mutation, i.e. AE1 mutation that codes for both band 3 protein in red blood cells, and bicarbonate/chloride exchanger on the basolateral membrane of renal collecting tubule alpha-intercalated cells (10). This is in contrast with AE1 mutation that was found in dominant form of familial dRTA in Western population, where the affected individuals had normal red cell morphology (10, 11). In fact, AE1 mutations has not been reported in recessive form of familial dRTA with normal red cell morphology (2). This underpins the recessivity of SAO mutation, causing dRTA only with the presence of a second band 3 mutations in the opposite allele. Different band 3 mutations such as substitution of glycine by aspartic acid at residue 701 (G701D) and deletion of valine in the 850 position ( $\Delta$ V850) were described in heterozygous compound with SAO mutation, leading to dRTA (10, 12).

Previous literature revealed that patients with RTA presenting with respiratory paralysis had hypokalemia with potassium level ranged between 0.8 mEq/L to 2.09 mEq/L with age group ranging between five and fifty-five years (7). Hypokalemia triggers skeletal muscle to release the stored potassium leading to respiratory muscle weakness (13). Systemic illnesses associated with respiratory failure in RTA include Sjogren syndrome, chronic active hepatitis, diabetes insipidus and interstitial nephritis (7). Our patient was 66 years old during the acute attack of respiratory failure and it was triggered by infection, AF and thyrotoxicosis. Different from previous literature, respiratory failure in our patient was primarily caused by a reduction in cerebral interstitial pH as a sequelae of severe metabolic acidosis in the plasma, which then stimulates the respiratory centre, leading to an increased rate of respiration as a result of carbon dioxide drive (14). Patient improved significantly after the correction of metabolic acidosis with sodium bicarbonate and oral Shohl's solution. Oxygen therapy was weaned off and she was discharged after 3 weeks of hospitalisation.

To the best of our knowledge, dRTA presenting with respiratory failure as a result of severe metabolic acidosis without typical hypokalaemia muscular paralysis, coupled with SAO in an older adult aged >65 years has not been described in Sarawak, Eastern region of Malaysia previously. This case highlights the importance of early recognition of dRTA in preventing complications such as chronic kidney disease, metabolic bone disease and life-threatening respiratory arrest. However, this was limited by unavailability of genetic testing to confirm the mutation causing the dRTA.

### Conclusion

Distal RTA is associated with Southeast Asian Ovalocytosis and may present with respiratory failure as a result of severe hyperchloremic metabolic acidosis, even without hypokalemia. Untreated distal RTA may lead to complications such as chronic kidney disease, metabolic bone disease and even respiratory arrest. Early recognition of distal RTA with alkalinizing treatment is paramount.

### Acknowledgement

Authors would like to thank all healthcare staffs involved in the management of the patient's care.

### Conflict of Interest

The authors declare that they have no competing interests.

### Ethical Approval

Ethical approval is not required at our institution to publish an anonymous case report.

### References

1. Soriano JR. Renal tubular acidosis: the clinical entity. *J Am Soc Nephrol.* 2002;13(8):2160-70.
2. Karet F, Gainza F, Györy A, Unwin R, Wrong O, Tanner M, *et al.* Mutations in the chloride-bicarbonate exchanger gene AE1 cause autosomal dominant but not autosomal recessive distal renal tubular acidosis. *Proc Natl Acad Sci U S A.* 1998;95(11):6337-42.
3. Yusoff NM, Van Rostenberghe H, Shirakawa T, Nishiyama K, Amin N, Darus Z, *et al.* High prevalence of Southeast Asian ovalocytosis in Malays with distal renal tubular acidosis. *J Hum Genet.* 2003;48(12):650-3.
4. Nurse G, Coetzer T, Palek J. The elliptocytoses, ovalocytosis and related disorders. *Baillieres Clin Haemat.* 1992;5(1):187-207.
5. Jarolim P, Palek J, Amato D, Hassan K, Sapak P, Nurse GT, *et al.* Deletion in erythrocyte band 3 gene in malaria-resistant Southeast Asian ovalocytosis. *Proc Natl Acad Sci U S A.* 1991;88(24):11022-6.
6. Mohandas N, Winardi R, Knowles D, Leung A, Parra M, George E, *et al.* Molecular basis for membrane rigidity of hereditary ovalocytosis. A novel mechanism involving the cytoplasmic domain of band 3. *J Clin Invest.* 1992;89(2):686-92.
7. Kalita J, Nair P, Kumar G, Misra U. Renal tubular acidosis presenting as respiratory paralysis: Report of a case and review of literature. *Neurol India.* 2010;58(1):106-8.
8. Hussin N, Lim YA, Goh PP, William T, Jelip J, Mudin RN. Updates on malaria incidence and profile in Malaysia from 2013 to 2017. *Malar J.* 2020;19(1):55.
9. Kimura M, Soemantri A, Ishida T. Malaria species and Southeast Asian ovalocytosis defined by a 27-bp deletion in the erythrocyte band 3 gene. *Southeast Asian J Trop Med Public Health.* 2002;33(1):4-6.
10. Wrong O, Bruce LJ, Unwin RJ, Toye AM, Tanner MJ. Band 3 mutations, distal renal tubular acidosis, and Southeast Asian ovalocytosis. *Kidney Int.* 2002;62(1):10-9.
11. Bruce LJ, Cope DL, Jones GK, Schofield AE, Burley M, Povey S, *et al.* Familial distal renal tubular acidosis is associated with mutations in the red cell anion exchanger (Band 3, AE1) gene. *J Clin Invest.* 1997;100(7):1693-707.
12. Bruce LJ, Wrong O, Toye AM, Young MT, Ogle G, Ismail Z, *et al.* Band 3 mutations, renal tubular acidosis and South-East Asian ovalocytosis in Malaysia and Papua New Guinea: loss of up to 95% band 3 transport in red cells. *Biochem J.* 2000;350(1):41-51.
13. Vasquez-Rios G, Westrich DJ, Philip I, Edwards JC, Shieh S. Distal renal tubular acidosis and severe hypokalemia: a case report and review of the literature. *J Med Case Rep.* 2019;13(1):103.
14. Tyagi A, Rautela R, Bhattacharya A. Renal tubular acidosis presenting with respiratory arrest. *Indian J Pediatr.* 2002;69(2):197.