

OBSTRUCTED OBTURATOR HERNIA WITH LAPAROSCOPIC APPROACH REPAIR

Khoo KS¹, Abdul Manan MA¹, and Wong WJ².

¹Surgical Resident, Department of Surgery, Faculty of Medicine, University of Malaya, 50603 Kuala Lumpur, Malaysia

²General Surgeon, Department of Surgery, Faculty of Medicine, University of Malaya, 50603 Kuala Lumpur, Malaysia

Correspondence:

Dr Khoo Kah Seng,

Surgical Resident, Department of Surgery,

Faculty of Medicine,

University of Malaya, 50603 Kuala Lumpur, Malaysia

Email: khseng901209@gmail.com

Phone number: 0379492441

Abstract

Obturator hernia is an uncommon intra-abdominal hernia with the incidence of 0.05-1.4% of all hernias. Diagnosis is often delayed as the clinical picture is usually non-specific and poses a diagnostic challenge to clinicians. This report describes a case of an 80-year-old woman, who presented to the Emergency Department with left lower quadrant abdominal pain that radiates to the left hip region for one day. Plain abdominal radiography showed dilated loops of small bowel in the pelvic region. Contrast Enhanced Computed Tomography (CECT) of abdomen and pelvis demonstrated left obturator hernia with small bowel obstruction. Emergency laparoscopic obturator hernia repair was performed. Intraoperative findings confirmed a left incarcerated obturator hernia. The small bowel was reduced and viable. Subsequently, a primary closure of the hernia orifice was performed. This case report emphasizes the successful use of a laparoscopic approach in obstructed obturator hernia and its feasibility in an emergency setting.

Keywords: Laparoscopic, Obturator Hernia, Small Bowel Obstruction

Introduction

Obturator hernia was first reported by Amaud de Ronsil in the year of 1724, and it commonly affects the female gender more than the male gender (1). Multiple factors predispose to the development of obturator hernias including chronic increase in intra-abdominal pressure, weight loss with reduced peritoneal fat and multiparity (1). The presentation of obturator hernia is often non-specific and commonly leads to delayed diagnosis and management. Laparotomy hernia repair is usually the treatment of choice in emergency setting such as obstruction or strangulation (2). We report a case of an elderly woman who was diagnosed with obstructed obturator hernia and was successfully managed with laparoscopy approach repair. This case report is presented in accordance with CASE (CASE REPORT) guidelines (3).

Case report

An 80-year-old woman with a thin build with underlying chronic lung fibrosis, presented to the Emergency Department with left lower quadrant abdominal pain that radiated to the left hip region for one day. The pain was associated with multiple episodes of vomiting. She was still able to open her bowels and pass flatus. She was hemodynamically stable and afebrile on arrival.

Abdominal examination revealed a distended lower abdomen. The inguinal hernial orifices were intact. The abdomen was tender at the left lower quadrant but there was no sign of peritonitis. Collapsed rectum found on digital rectal examination. A nasogastric tube was inserted yielding minimal output. Biochemical investigations were unremarkable. Her total white count, renal profile and electrolytes were within the normal range, no acidosis on blood gas. Initial plain abdominal radiography showed dilated loops of small bowel at the pelvic region (Figure 1). A Contrast Enhanced Computed Tomography (CECT) of the abdomen and pelvis was performed to investigate the aetiology of the small bowel obstruction. The CECT demonstrated a left obturator hernia with small bowel obstruction (Figures 2 & 3).

She was booked for an emergency laparoscopic obturator hernia repair. A careful insertion of an infra-umbilical 12 mm camera port was performed via Hassan technique and the abdomen was insufflated with carbon dioxide. Two 5 mm working ports were inserted at the right hypochondrium and left hypochondrium regions respectively. Intraoperative findings confirmed a left obturator hernia with small bowel dilatation proximal to the obstructed hernia (Figures 4 & 5). The incarcerated small bowel was reduced using non-traumatic forceps. On assessment, the small bowel was deemed viable. Subsequently, the hernia orifice closed

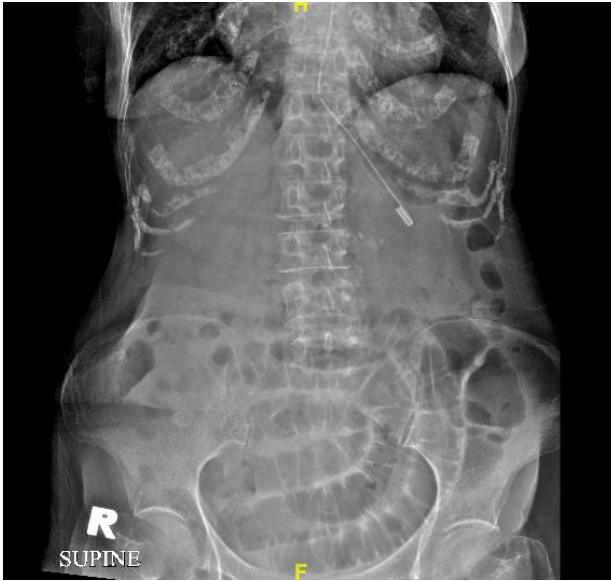

Figure 1: Dilated small bowel loops at the pelvic region

primarily by interrupted non-absorbable polypropylene sutures (Figure 6). The patient had a speedy recovery, and she was discharged home after 3 days of surgery. No recurrences or complications were noted during out-patient follow-up.

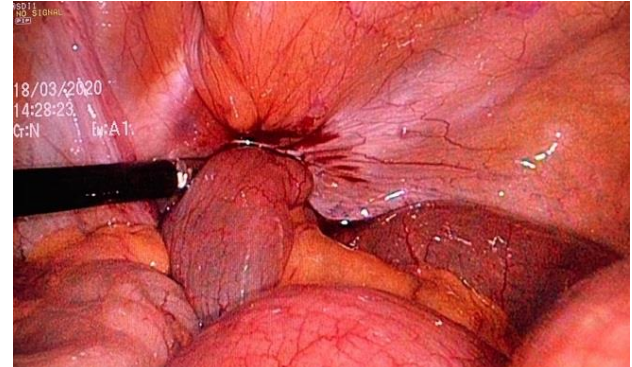


Figure 4: Left obturator hernia with small bowel incarcerated

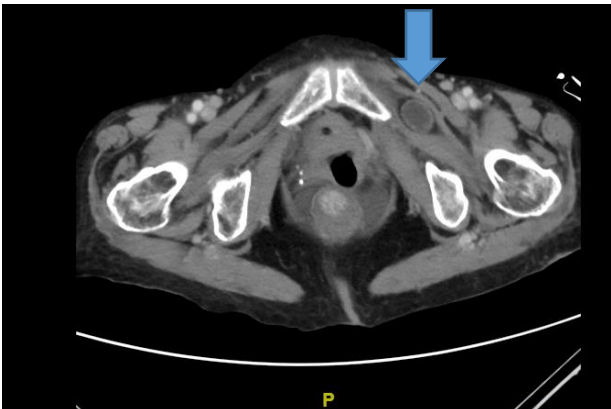


Figure 2: Left obturator hernia with bowel content on CECT-abdomen/pelvis (Axial view)

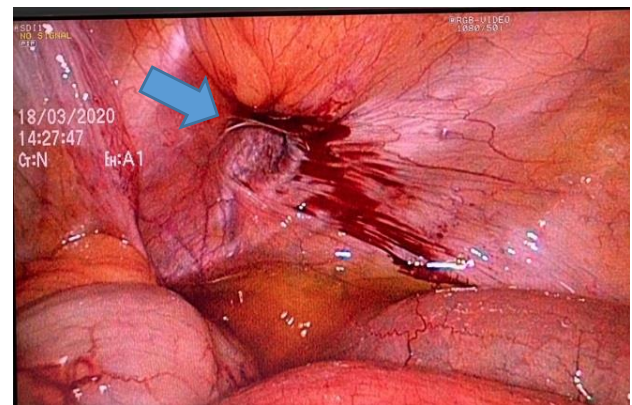


Figure 5: Left obturator hernia defect (approximately 1cm in size) after contents reduced

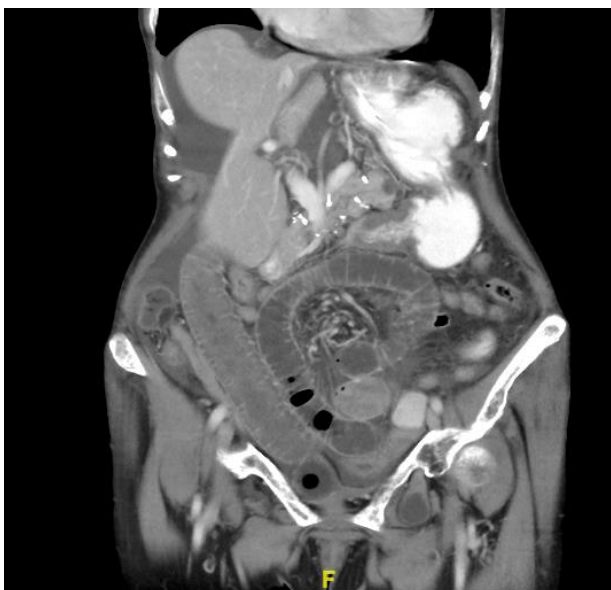

Figure 3: Left obturator hernia with small bowel dilatation on CECT-abdomen/pelvis (Coronal view)

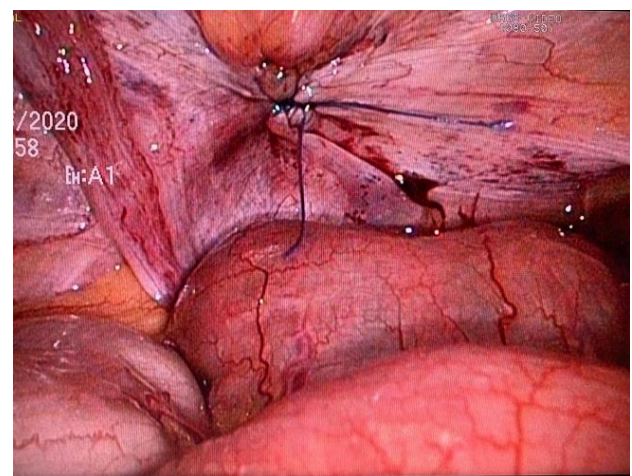


Figure 6: Hernia orifices repaired with non-absorbable suture

Discussion

Females are affected nine times more frequently than males for obturator hernia. A larger pelvis size and larger foramina increases the likelihood of defects forming (2). In this case, our patient is a thin elderly lady (BMI: 19.5) with underlying chronic lung fibrosis which increases her risk of obturator hernia.

The obturator foramen is a large opening bounded by the ischium and pubis bones of the pelvis through which neurovascular bundles pass. The obturator foramen is bounded by obturator membrane except at the anterior superior aspect in which the hernia descends.

The clinical presentation of obturator hernia is often non-specific and hence difficult to diagnose (2). Eighty percent of the cases will present with symptoms of bowel obstruction which include colicky abdominal pain, vomiting and nil bowel opening or flatus (4). Obstruction is usually partial as 40% of the cases reported are due to Richter's herniation of small bowel into the obturator canal (4). The pathognomonic Howship–Romberg sign, which is described as pain along the distribution of the obturator nerve, is seen in only 37% of patients. The pain is usually worsened by the medial rotation and adduction of the hip and relieved by the flexion. This is due to the compression on the obturator nerve during this manoeuvre. Presence of this sign should raise the physicians' index of suspicion (4-6). High morbidity and mortality in obturator hernias are usually related to advanced age, delay in diagnosis, gangrene and bowel perforation and associated chronic diseases.

CECT of the abdomen and pelvis has a sensitivity ranging from 90% to 100% (7). It plays an important role in diagnosis as clinical diagnosis of obturator hernia is difficult (4, 6, 7). This imaging modality can demonstrate incarcerated bowel, perforation or ischaemia. A pre-operative CECT is helpful when performed early, in the planning of early intervention in frail or elderly patients. Hence, we recommend an urgent CECT of the abdomen and pelvis when there is a high index of suspicion for obturator hernias.

Obturator hernia was first successfully treated by Henry Obre in 1851 (8). Traditionally, an obturator hernia repair in an emergency setting is performed via laparotomy. Several published reports have shown the feasibility and safety of laparoscopic approaches for the management of incarcerated obturator hernias (3-5, 7). Among the laparoscopic methods, the transabdominal preperitoneal repair is the preferred technique as it allows visualization of the visceral contents especially in emergency setting. A total of 28 cases of obturator hernia (performed electively and under emergency) were included in a systemic review by Deeba *et al.* in 2011 (5), where all the cases were repaired using a laparoscopic approach. There were 8 transabdominal preperitoneal (TAPP) mesh repairs, 15 totally extraperitoneal (TEP) mesh repairs, 4 direct repairs by primary stapling or suturing and one

intraperitoneal plug repair (5). No recurrence was reported in all the 28 cases. The median follow-up period was 1 year. Another retrospective cohort study by Nasir *et al.* which included 30 patients treated with open and laparoscopic repair (including primary and mesh repair) reported no recurrences within a median follow-up period of 2 years (7). The TEP approach is not encouraged in the emergency setting as this method cannot assess the bowel especially in the case of a strangulated obturator hernia.

There are many techniques for the repair of obturator hernias. These include the use of fascial and muscular flaps, peritoneal covering, omental fat plugs, mesh repair or closure with non-absorbable sutures (3, 5, 9). Intracorporeal sutures should be placed over the anterior superior defect of the obturator foramen as the obturator membrane covers the foramen except for anterior superior aspect, where the hernia descends. Based on current evidence, primary repair and mesh repair yields similar results with no recurrences being reported within a median follow up period of 2 years (7). There is currently not enough evidence to suggest which method is superior.

In this case, the hernia orifice was approximately 1 cm in size. Primary repair with non-absorbable suture was chosen to shorten the duration of surgery in view of patient's advanced age and underlying co-morbidities. To date, primary or mesh repairs have yielded similar results in term of success and recurrence rates regardless of the size of the defect.

Absolute contraindications for laparoscopic surgery include generalized peritonitis, hypovolaemic shock, severe cardiac disease and uncorrectable coagulopathy. Laparoscopic procedures in elderly patient with chronic lung disease can be challenging. Knowledge of pre-operative pulmonary function and good communication with the anaesthetic team are vital. This will enable anaesthetists to monitor end-tidal carbon dioxide and arterial blood gasses, adjust ventilation rates and pressure. Apart from that, surgeons should aim to maintain low insufflation pressures below 12 mmHg to minimise physiological disturbances caused by carbon dioxide gas insufflation during laparoscopic surgery.

Conclusion

Obturator hernias are uncommon and usually present emergently. The diagnosis should be suspected when a thin elderly woman presents with bowel obstruction or non-specific pain over the thigh and hip. CECT is the imaging modality of choice to diagnose this condition. Laparoscopic obturator hernia repair is feasible in an emergency setting.

Financial support

None.

Competing interests

The authors declare that they have no competing interests.

Ethical clearance

The authors are accountable for all aspects of the work in ensuring that questions related to the accuracy or integrity of any part of the work are appropriately investigated and resolved. All procedures performed in studies involving human participants were in accordance with the ethical standards of the institutional research committee and with the Helsinki Declaration (as revised in 2013). Written informed consent was obtained from patient for any accompanying images and publication of this study.

References

1. Hsu CH, Wang CC, Jeng LB, Chen MF. Obturator hernia: a report of eight cases. *Am Surg.* 1993;59(11):709-11.
2. Lynch NP, Corrigan MA, Kearney DE, Andrews EJ. Successful laparoscopic management of an incarcerated obturator hernia. *J Surg Case Rep.* 2013;2013(7):rjt050.
3. Riley DS, Barber MS, Kienle GS, Aronson JK, TV Schoen-Angerer Tugwell P, *et al.* CARE guidelines for case reports: explanation and elaboration document. *J Clin Epidemiol.* 2017;89:218-35.
4. Malik MU, Connelly TM, Hamid M, Pretorius F. Laparoscopic total extraperitoneal repair of preoperatively diagnosed bilateral obturator and incidental bilateral femoral herniae. *BMJ Case Rep.* 2016;2016:bcr2016214978.
5. Deeba S, Purkayastha S, Darzi A, Zacharakis E. Obturator hernias: a review of the laparoscopic approach. *J Minim Access Surg.* 2011;7(4):201-4.
6. Tee CL, Evans T, Ratnayake S, Strekozov B. Small bowel obstruction secondary to bilateral obturator hernia: a rare occurrence. *J Surg Case Rep.* 2014;2014(2):rju009.
7. Nasir BS, Zendejas B, Ali SM, Groenewald CB, Heller SF, Farley DR. Obturator hernia: the Mayo Clinic experience. *Hernia.* 2012;16(3):315-9.
8. Aydin I, Yucel AF, Pergel A, Sahin DA. Obturator hernia: a rare case of acute mechanical intestinal obstruction. *Case Rep Surg.* 2013;2013:256062.
9. Norly S, Chua SH, Rosaini P. Obturator hernia: the little old lady's hernia, a case series. *Sch J Med Case Rep.* 2017;5(10):685-7.